

Pan-African Journal of Plastic Reconstructive and Aesthetic Surgery Vol. 2 No. 1 March 2025

HARNESSING THE POWER OF A CONTRALATERAL PARAUMBILICAL FLAP IN COVERING A RIGHT VOLAR DISTAL FOREARM WOUND: A CASE REPORT

K. Chesoni, L.Munge, W. Adegu, and F.W.Nang'ole, PhD, Department of Plastic and Reconstructive and Aesthetic Surgery, University of Nairobi, Kenya

Corresponding Author: Dr. Chesoni Kevin, Department of Plastic and Reconstructive and Aesthetic Surgery, University of Nairobi, Kenya Email: chesonik@gmail.com

HARNESSING THE POWER OF A CONTRALATERAL PARAUMBILICAL FLAP IN COVERING A RIGHT VOLAR DISTAL FOREARM WOUND: A CASE REPORT

K. CHESONI, L.MUNGE, W. ADEGU, AND F.W.NANG'OLE,

SUMMARY

The ipsilateral paraumbilical flap is frequently employed in upper extremity reconstruction. However, the contralateral paraumbilical flap offers a robust alternative for addressing complex volar distal forearm wounds, particularly when local tissue options are inadequate. This case report presents our experience utilizing a contralateral paraumbilical flap in the reconstruction of a right volar distal forearm defect following an electrical burn injury in an 8-year-old male patient.

The patient, who sustained a high-voltage electrical burn injury, underwent staged reconstruction from November 2023 to January 2024. A contralateral paraumbilical fasciocutaneous flap measuring 6 x 10 cm was raised and used for wound coverage. The patient reported satisfaction with the reconstructive outcome, expressing contentment with the overall functionality, despite the loss of the thumb and little finger. The flap provided stable coverage of vital structures with minimal donor site morbidity.

In conclusion, the contralateral paraumbilical flap is an effective reconstructive option for distal volar forearm defects, particularly in cases involving severe electrical injuries. This approach is characterized by ease of harvest, reliable vascularity, and a favorable profile of donor site complications.

Keywords: contralateral paraumbilical flap, upper extremity reconstruction, forearm volar defect.

INTRODUCTION

Electrical injuries to the upper extremities are often associated with significant morbidity, ranging from skin and soft tissue damage to deeper injuries involving muscles, nerves, and bones. High-voltage injuries, in particular, can cause severe tissue necrosis, posing a challenge in terms of wound coverage and reconstruction(1). In Kenya, such injuries are prevalent in informal settlements and frequently affect young males working near power lines(2). Reconstruction often necessitates tissue transfer from distant sites due to a lack of viable local tissue options(3) which can be a significant challenge for burn and plastic surgeons to reconstruct. This intensive and multistage reconstructive process is especially difficult in the growing child. Maximizing upper extremity function is a top priority, as it can

have a significant impact on a patient's quality of life. This report aims to highlight the versatility and applicability of the contralateral paraumbilical flap in managing complex upper limb injuries.

CASE PRESENTATION

An 8-year-old male patient presented with a severe right forearm wound resulting from a high-voltage electrical injury. After initial management and wound stabilization, a contralateral paraumbilical fasciocutaneous flap was utilized for reconstruction. The defect measured 6 x 10 cm and encompassed the distal volar forearm. The flap was harvested under general anesthesia, and the donor site was primarily closed. Short-term follow-up showed stable wound coverage with no significant complications at the donor site.

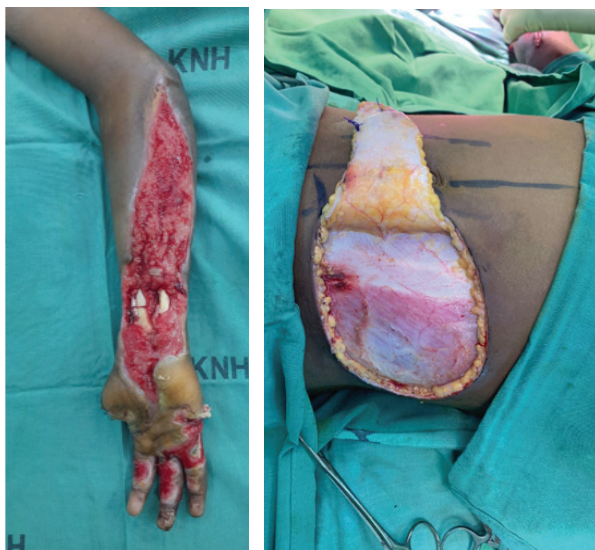


Figure 1: Initial defect on the left forearm and raised contralateral paraumbilical flap.

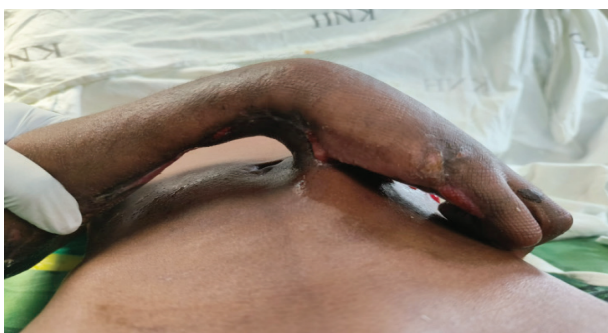

Figure 2: Flap in situ before division.

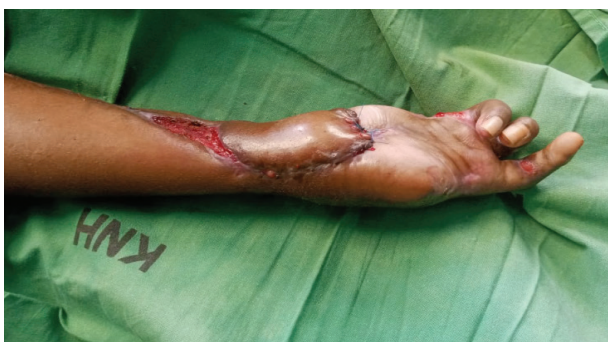

Figure 3: Final results post flap division.

OUTCOME ASSESSMENT

Assessment of outcomes following reconstruction with a contralateral paraumbilical flap revealed promising results in both functional and aesthetic aspects. The patient exhibited an improved range of motion, facilitating an early return to activities of daily living. Furthermore, the contralateral

paraumbilical flap covered all the vital structures at the distal forearm, with minimal donor site morbidity observed. Short-term follow-up indicated durable outcomes, underscoring the reliability and efficacy of this technique in upper limb reconstruction.

DISCUSSION

The contralateral paraumbilical flap offers a valuable option for covering volar distal forearm defects, especially in cases where local tissue is insufficient or unsuitable due to prior surgeries, infection, or trauma(1). Its rich vascular supply ensures reliable tissue perfusion, facilitating wound healing and minimizing the risk of flap failure. Additionally, this flap provides adequate tissue volume with minimal donor site morbidity.

In comparison to traditional methods, such as the radial forearm flap or free flap techniques, the contralateral paraumbilical flap circumvents the need for complex microvascular anastomoses, reducing operative time and associated risks(4). While free flaps like the anterolateral thigh (ALT) flap require advanced microsurgical skills and longer operative times, the contralateral paraumbilical flap offers a straightforward and effective solution with fewer complications(5).

However, patient selection is crucial. Factors such as overall health, body habitus, and specific wound characteristics must be considered to optimize outcomes. Despite the advantages, potential complications include donor site infection, seroma, and aesthetically concerning scarring.

CONCLUSION

The contralateral paraumbilical flap is a reliable and versatile option for distal forearm reconstruction, especially in cases of severe electrical injury. Its application minimizes the need for microsurgery while providing stable wound coverage with a low incidence of complications. Further research with larger patient samples is warranted to validate these findings and establish guidelines for its use.

REFERENCES

1. Bijli AH, Bashir SA, Rasool A, Yasir M, Wani AH, Ahmad T, *et al.* Contralateral lumbo-umbilical flap: A versatile technique for volar finger coverage. *Indian J Plast Surg.* 2017; **50**(2):201–6.

-
2. 345 people electrocuted in the last three years – Kenya Power – Kenya News Agency [Internet]. 2021 [cited 2024 Oct 7]. Available from: <https://www.kenyanews.go.ke/345-people-electrocuted-in-the-last-three-years-kenya-power/>
 3. DePamphilis M, Cauley R, Sadeq F, Lydon M, Sheridan R, Winograd J, *et al.* Reconstruction of the Upper Extremity High-Voltage Electrical Injury: A Pediatric Burn Hospital's 13-Year Experience. *Journal of Burn Care & Research*. 2021 Sep **17**:43.
 4. Goertz O, Kapalschinski N, Daigeler A, Hirsch T, Homann HH, Steinstraesser L, *et al.* The effectiveness of pedicled groin flaps in the treatment of hand defects: results of 49 patients. *J Hand Surg Am*. 2012 Oct;**37**(10):2088–94.
 5. MS, NO, GG, SB. Microvascular reconstruction in burn and electrical burn injuries of the severely traumatized upper extremity. *Plastic and reconstructive surgery* [Internet]. 2007 Feb [cited 2024 Oct 7];119(2). Available from: <https://pubmed.ncbi.nlm.nih.gov/17230097/>